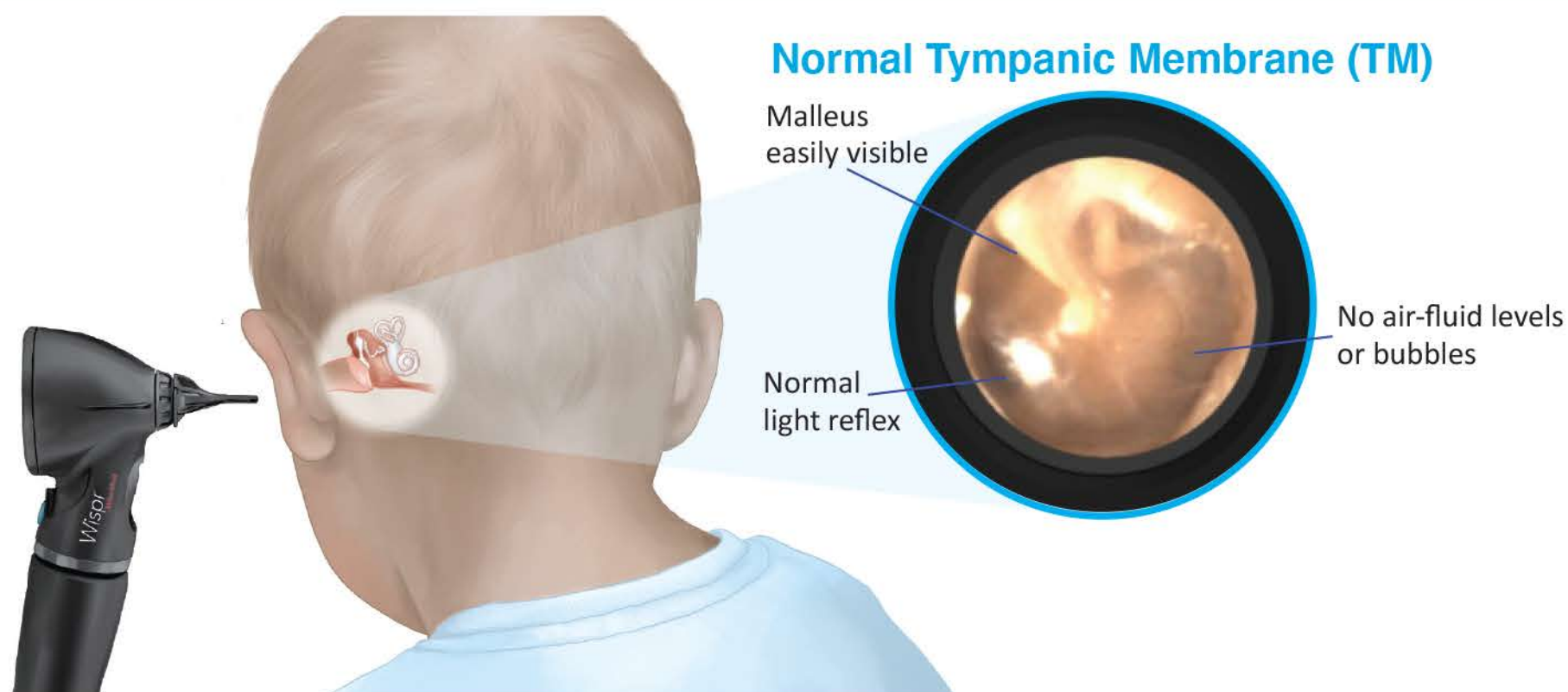


Visual Guide to Acute Otitis Media



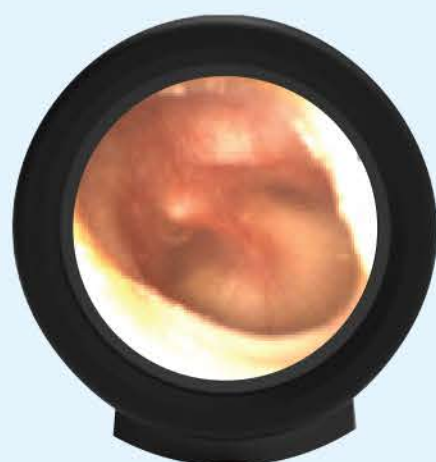Diagnosis of Acute Otitis Media (AOM)

Moderate to severe TM bulging **-OR-**

Mild TM bulging **AND** recent onset of ear pain or intense erythema

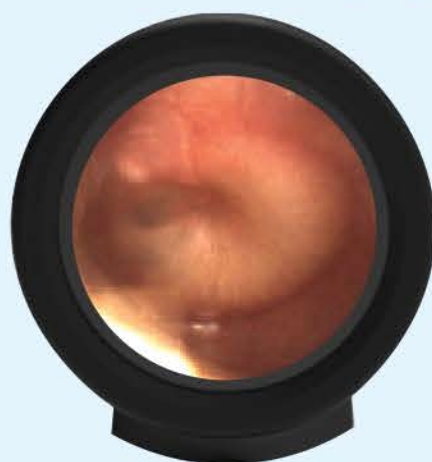American Academy of Pediatrics Practice Parameter

Mild Bulging



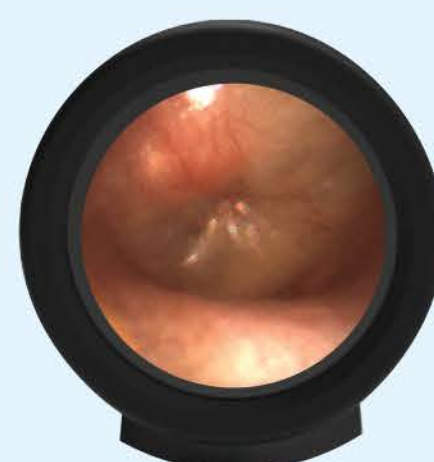Shallow central dimple
Malleus not clearly visualized

Moderate Bulging



Dimple deepens

Severe Bulging



TM looks like a donut
Malleus barely visible

AOM Severity Assessment

Severe if more than 48 hours of increased ear pain OR higher fever ($\geq 39^{\circ}\text{C}$)

Nonsevere if less than 48 hours of mild ear pain AND lowgrade fever ($< 39^{\circ}\text{C}$)

Treatment for Nonsevere AOM*

Younger than 6 months: prescribe antibiotics

6-23 months old and bilateral: prescribe antibiotics

6-23 months old and unilateral: 48-72 hours observation & delayed prescription

Older than 24 months: 48-72 hours observation & delayed prescription

*Treat all severe AOM or otorrhea from TM perforation with antibiotics

Antibiotic Duration

≤ 2 years 10 days

2-5 years 7 days

≥ 6 years 5 days